

## Role of Endonasal Endoscopic Dacryocystorhinostomy In Dacryocystitis

Dr. Nirupama Moran<sup>1</sup>, Dr. Pinpo Teron<sup>2</sup> Dr. Joydeep Dey<sup>3</sup>  
<sup>1,2,3</sup>(Otorhinolaryngology and Head & Neck Surgery /Assam Medical College & Hospital,  
Dibrugarh, Assam, India)

**Abstract:** A prospective study was carried out in the department of Otorhinolaryngology in the Assam Medical college and Hospital, Dibrugarh. Between the October 2012 to September 2014. A total 56 cases were taken, having Epiphora, Acute-on- chronic Dacryocystitis following nasolacrimal duct (NLD) obstruction and common canalicular block. Those having noticeable lid laxity, post traumatic lid and bony deformity, Dacryolith, Traumatic obstruction, Suspicion of Malignancy, Previous radiation therapy were excluded. Success was defined as grade 0,1 and 2 Epiphora, 0 being complete patency of lacrimal drainage system confirmed by irrigation at 3 months follow-up. Out of 56 cases, 48 were Female and 8 were Male. . The age of the patients ranged from 17- 48 years. All had unilateral NLD obstruction. All 40 had persistent Epiphora, while 16 had purulent discharge. Most of the patients, 30 had two years H/O Epiphora and 16 had less than one year. 48 patients had the procedure performed successfully. Complications include synechiae (3 patients), 5 patient had granulation at the Rhinostomy site. Endo DCR is a valid alternative to external procedure in the management of NLD obstruction. It is a less invasive procedure and efficacious method with high success rate and good outcome.

**Keywords** - Endo DCR , nasolacrimal duct (NLD), Dacryocystitis

---

### I. Introduction

Inflammation of the lacrimal sac is known as dacryocystitis. It may occur in two forms: (1) congenital and (2) adult dacryocystitis. Congenital dacryocystitis is almost always chronic, while acquired (adult) may be acute or chronic. Acute dacryocystitis may be acute inflammation of the sac or to suppuration starting in the pericyclic tissues. Chronic dacryocystitis is a more common condition. Dacryocystorhinostomy is a procedure performed to drain the lacrimal sac in cases of nasolacrimal duct obstruction or in chronic dacryocystitis.

### Aims And Objectives

To study the efficacy of Endoscopic Dacryocystorhinostomy (Endo DCR) in dacryocystitis.

### II. Materials And Methods

This prospective type of study was conducted in the Department of Otorhinolaryngology and Head & Neck Surgery, Assam Medical College & Hospital, Dibrugarh. 56 cases are taken those attending the outpatient and inpatient department. The Study was done October 2012 to September 2014. *exclusion criteria* are Noticeable lid laxity, Post traumatic lid and bony deformity, Dacryolith, Traumatic obstruction, Suspicion of malignancy, Previous radiation therapy. In the OPD patient particulars and disease history was taken thoroughly

**Chief Complaints And History Of Present Illness:** Epiphora, Mode of onset, Laterality, Duration of Epiphora, Swelling below the medial canthal area, Duration of swelling, Pain over the swelling. **Other Complaints:** Running nose and nasal blockage, Visual disturbances, Stickiness of the lids due to regurgitation of pus.

**Past History:** Any major traumatic facial injury, Any major nasal surgery. **Clinical Examination:** Appearance, Build, Nutrition, Pallor, Icterus, Cyanosis, Oedema, Koilonychias, Clubbing, Dehydration, Pulse, Blood Pressure, Respiratory rate. **Eye Examination:** Examination of lids and placement of puncta, All patients had normal lid function and placement of puncta with no ulcer and growth were included in this study. **Roplas**

**Regurgitation Test:** Pressure over the lacrimal sac were done to all the cases and pus came out from the lower punctum seen, Positive ROPLAS test indicates block at the level of nasolacrimal duct. **Probing:** All selected patients were probed with Bowman's probe to see the level of obstruction. **Syringing:** All 25 cases shows regurgitation through the opposite punctum. External and intranasal examination was done. Diagnostic nasal endoscopy was done to identify nasal pathology and also assessing the post operative result. **Routine**

hematological examination was done. Radiological Examinations: X-Ray Nose and PNS, Water's View, X-Ray Chest (PA View).

**Operative Technique**

The key landmark is the ridge formed by the frontal process of maxilla and the root of the middle turbinate on the lateral nasal wall. Local infiltration of lacrimal sac area is done. Vertical incision is made 1-1.5 cm anterior to the base of the uncinat process vertically downed till the anterior end of the middle turbinate. Overlying mucosa is separated using a blunt dissection, ledge of the bone is identified, the Kerrison bone punch is hooked against the posterior part of the anterior lacrimal crest. Posteriorly the bone is thin and can be removed easily, this is followed by anterior removal of the bone. After identification of the lacrimal sac. Whole of the medial wall is removed. Syringing done. The mucosal flap is then placed over the remaining frontal process of maxilla, if nasal pack required than it is given cautiously over the window.

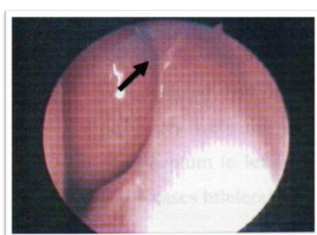


Fig-1

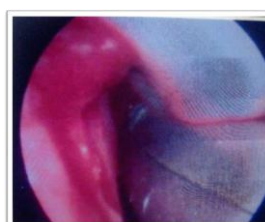

Fig-2

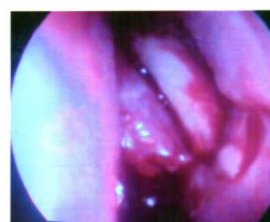

Fig-3

**Follow-up:** will be done at 48 hours after surgical procedure, at 1 week,2 weeks,6 weeks,10 weeks and 3months.

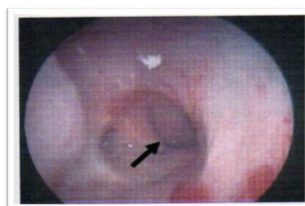


Fig-4

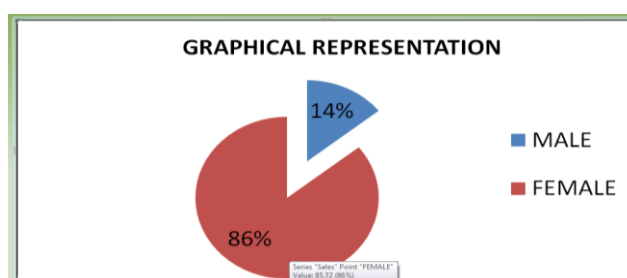
**Postoperative Management**

Packing of the nasal cavity is done for 24-48 hours. Systemic antibiotics, decongestant are given 1 week. Analgesic and serratiopeptidase is given as per requirement. Oxymetazoline nasal drop was given. Antibiotic eye drop was for a week in the operated site. Syringing is done on day 2,7 ,weeks-2,6 and 3 months.

**III. Result And Observations**

Age group in years	Numbers (n=56)	(%)
11-20	10	17.86
21-30	25	44.65
31-40	10	17.86
41-50	8	14.28
51-60	3	5.35
total	56	100

Sex distribution	No. of cases	(%)
Male	8	14.28
Female	48	85.72
Total	56	100



## *Role of Endonasal Endoscopic Dacryocystorhinostomy In Dacryocystitis*

Presenting features	No. of patients	%
Epiphora	56	100
Swelling of lower lid below medial canthal area	15	26.79
Discharge of pus from the swelling	20	35.72
Nasal blokage with epiphora	12	42.8

Consistency of swelling	No. of cases(n=56)	(%)
Cystic	13	23.21
Solid	0	0
Tenderness	2	3.57

Findings	1 Wks	2 Wks	6 Wks	10 Wks	3 Mnts
Complete Relief	48	48	48	48	48
Partial Relief	0	0	3	3	3
No Relief	0	4	5	5	5

Intra-operative complications	No. of cases (n=56)	%
Excessive bleeding	1	1.78
Injury to lamina papyracea	0	0
Severe lid odema	1	1.78
Cerebrospinal fluid leak	0	0

Late post operative complication	No. of cases(n=56)	(%)
Granulation at the rhinostomy site	5	8.92
Adhesion or synechia	3	5.35
Scarring at the rhinostomy site	0	0

### IV. Discussion

EnDCR is indicated for congenital and acquired nasolacrimal duct obstruction.<sup>[1]</sup> Chronic dacryocystitis is more common in women of low socio economic group due to their bad personal habits, long duration of exposure to smoke in kitchen and dust in the external environment.<sup>[2]</sup> Other possible causes are congenital and anatomical narrowing of nasolacrimal drainage system females as compared to males.<sup>[2]</sup> The first report of dacryocystorhinostomy (DCR) was by Caldwell in 1893.<sup>[3]</sup> He created a rhinostomy using an intranasal approach by removing a part of inferior turbinate and following the nasolacrimal duct to the lacrimal sac. Toti, in 1904 is credited with the description of an external approach more than a decade after Caldwell has described the operation via the endonasal approach. Endoscopic dacryocystorhinostomy (Endo-DCR) is a commonly performed operation in which a fistulas tract is created between the lacrimal sac and the nasal cavity in order to relieve the epiphora due to nasolacrimal duct obstruction. Endonasal DCR has certain advantages over external DCR, No external scar, Relatively bloodless surgery, Better visualization of nasal pathology, Less chances of injury to the ethmoidal vessels and cribriform plate, Less time consuming (15–30 minutes) since nasal mucosal flaps and sac, No postoperative morbidity, In this study -----out 56 cases, 48 patients had the procedure performed successfully, Our success rate is 85.71%, Success was defined as grade 0,1 and 2 epiphora, 0 having complete patency of lacrimal drainage system confirmed by irrigation at 3 months, Complications included synechia 3 patients ,5 patients has granulation at rhinostomy site.

### V. Conclusion

ENDO DCR is a valid alternative to external procedure in the management of nasolacrimal duct obstruction. It is less invasive procedure and efficacious method with high success rate and good outcome.

### References

- [1]. Coden DJ, Hornblase A, Haas BD (1993) Clinical bacteriology of dacryocystitis in adults. *Ophthal Plast Reconstr Surg* 9:125–131
- [2]. El-Guindy A, Dorgham A, Ghoraba M (2000) Endoscopic revision surgery for recurrent epiphora occurring after external dacryocystorhinostomy. *Ann Otol Rhinol Laryngol* 109:430–435
- [3]. Caldwell GW: Two new operations for obstruction of the nasolacrimal duct, *NYJ Med* 1893,57:581-582.