

Inguinal Hernia in children: conventional Open herniotomy procedure verses Laparoscopic Surgery- A Comparitive study

Dr.Sipala Siva kumar¹, Dr.T.Vittal Mohan²

Dept. of Paediatric Surgery, S.V.Medical College, SVRRGG Hospital, Tirupati, Dr. NTR University of Health Sciences, A.P., India.

Abstract:

Aim: To compare the conventional Open herniotomy with the Laparoscopic surgery in children with Unilateral Inguinal hernia over a period of one year prospectively from June 2014 to June 2015 at SVRRGG Hospital, a tertiary care hospital attached to S.V.Medical College at Tirupati.parameters include duration of surgery, recovery, post operative pain, post operative complications, discharge, recurrence and cosmesis.

Patients and methods: Total of 132 cases attended to opd during June 2014 to June 2015. but only 40 cases of Unilateral inguinal hernias [20 open surgery+20 laparoscopic surgery] ,age group between 2years to 12 years were taken into consideration, average hospital stay was 37 hrs.

Results: Of the 40 children with unilateral inguinal hernias Male were=36 and female were 4 ratio being 9:1, hernias were clinically right-sided in 29 (72.5%) patients and left sided in 11 (27.5%) .post operative pain is almost similar in both procedures, recurrence noted in 1 case of lap surgery. cosmesis is excellent in lap surgery.

Conclusion: cosmesis is superior and wound infection is less in laparoscopic surgery and its ability to inspect for contralateral processus vaginalis and simultaneous repair is an added advantage.

Key Words: Inguinal Hernia, children, Open herniotomy, Laparoscopy.

I. Introduction

Inguinal hernia has been recognised as far back as 1500 BC. however modern hernia surgery has began in the 19th century. Surgery for inguinal hernia is one of the commonest operation performed in children and the reported incidence is 0.8 to 4.4%. [1]. Laparoscopic Surgery for paediatric inguinal hernia is emerged as an alternate procedure to open herniotomy.

II. Patients And Methods

It is a prospective study of one year from June 2014 to June 2015 a total of 132 children with inguinal hernias were attended to OP D .out of which 89 cases were registered for surgery. among which bilateral inguinal hernias and children below 2years were excluded from this study because of paediatric anaesthesia and beginning of this procedure at our center. Age between 2years to 12 years with Unilateral inguinal hernias were taken into sideration. For 20 children conventional Open herniotomy and in other group of 20 children laparoscopic surgery performed and results analysed parameters include duration of surgery, recovery, post operative pain, post operative complications, discharge, recurrence and cosmesis. Protocols for pre and post operative care were predetermined to ensure uniformity.

Pre operative workup:

All patients were admitted a day before surgery. Routine investigations like Complete blood picture , Bleeding and Clotting time, Blood grouping and typing, Urine examination and screening for HIV and HBSAG were performed at our centre. Patients were kept on fasting for 5 hours before surgery and informed consent from all parents were obtained.

Anaesthesia:

All surgeries performed under general endotracheal anaesthesia for this study before induction all children were given injection ceftriaxone as antibiotic 50 mg/kg.

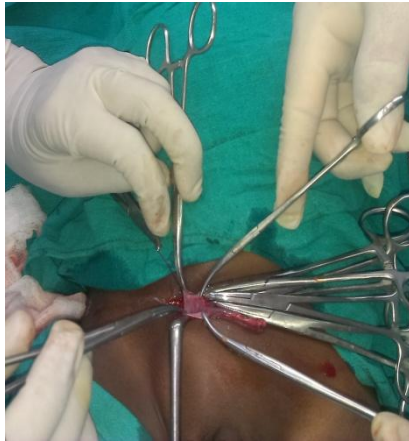Surgical technique:

Conventional Open herniotomy: Performed using an inguinal skin crease incision of size 1 inch. Herniotomy done using 3/0 absorbable (vicryl) suture.

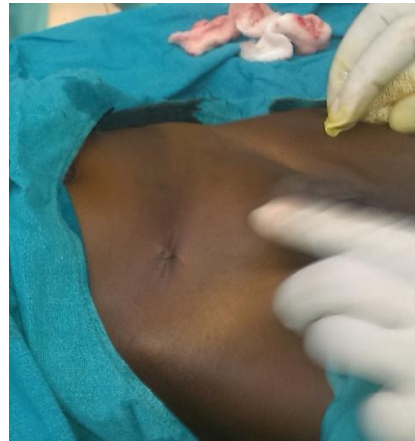Laparoscopic surgery: The standard three 5-mm ports technique with an intra-abdominal pressure of 8 mm Hg. The internal ring was obliterated by purse string suture using 3-0 prolene, introduced directly through the anterior abdominal wall.

Post operative analgesia: Diclofenac sodium 1mg/kg was given 8th hrly orally.

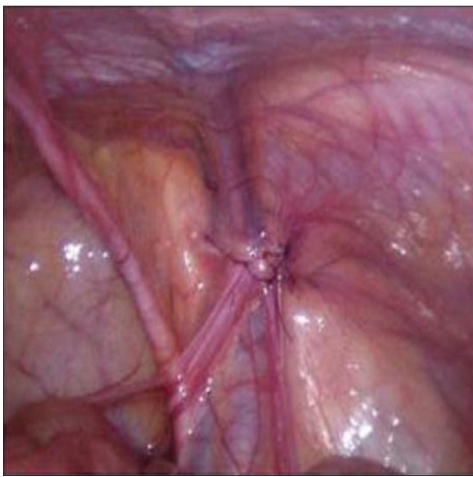
Followed up: Patients were followed up for an average of 4 months to evaluate these outcomes.



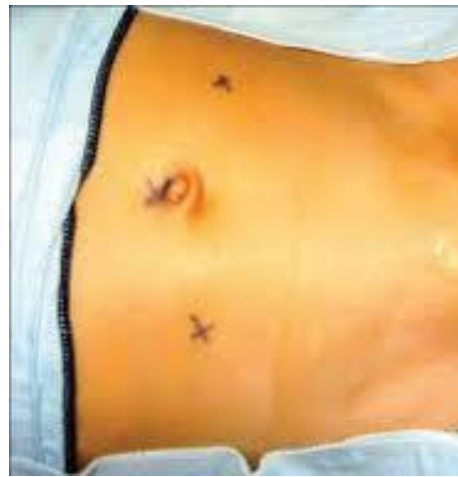Conventional Open herniotomy



Post operative Scar in Open herniotomy



Internal ring is closed with Purlsting Suture



Post op Scars in Laparoscopy

III. Results

Of the 40 children with unilateral inguinal hernias Male were=36 and female were 4: sex ratio being 9:1, hernias were clinically right-sided in 29 (72.5%)[m=27+f=2] patients and left sided in 11 (27.5%) [m=9+f=2]. Because small sample size statistical analysis not done.

Parameter	open [n=20]	lap[n=20]
Age (Mean)	5.1YRS	5.0YRS
Sex		
Male	18	18
Female	2	2
Side of Hernia		
Right	18	9
Left	2	11
Duration of Surgery	25.20	40.31
Pain	3	4
Recovery < 3hrs	20	18
Recovery > 3hrs	0	1
Discharge < 24 hrs	15	19
Discharge >24 hrs	5	1
Complications		
Wound Infection	3	1
Recurrence	0	1
Cosmesis	Good	Excellent

IV. Discussion

Pediatric Inguinal Hernia is a common problem and open herniotomy is standard treatment as it is easy to perform and with high success rate and low rate of complications[2]. Because of wide use of laparoscopy in different fields, is gaining popularity in pediatric hernia surgery as well[3] Most practiced lap procedure is standard 3 port technique involving intracorporal knotting of the internal ring [4].But the need to investigate further for the superiority of one procedure over other. Although the lap procedure.laparoscope proves added advantage in simultaneous repair of patent processus vaginalis but the repair of non symptomatic cppv is a controversial issue[5].As we are trained in open procedure the learning curve for lap procedure is long.post op pain almost similar in our series ,wound infection is less and cosmesis is excellent in laparoscopic surgery.

V. Conclusion

The standard conventional Open herniotomy is equally effective as to laparoscopic surgery. open procedure may be performed where the facilities for laparoscopy is not available. But excellent intraoperative viewing,improved post surgical cosmesis and its detection and simulataneous repair of contralateral processus vaginalis are the advantages of laparoscopic procedure. however to come to conclusion of which procedure is superior over other many more controlled and randomized studies are required.

References

- [1]. Philp L. Glick and Scott C.Boulanger Inguinal Hernias and Hydroceles in Arnold G.Coran, Pediatric Sugery, 7TH Edition,Chapter 76, Elsevier saunders 2012,Vol 2, pages985 to1001.
- [2]. Lloyd DA, Rintala RJ. Inguinal hernia and hydrocele. In: O'Neill JA Jr, Rowe MI, Grosfeld JC, et al., editors. (eds). Pediatric Surgery. St Louis, MO: Mosby; 1998;1071–1086. [Pub Med]
- [3]. Saranga Bharathi R, Arora M, Baskaran V. Minimal access surgery of pediatric inguinal hernias: a review.Surg Endosc. 2008. April 9 [Epub ahead of print] . [Pub Med]
- [4]. Schier F, Montupet P, Esposito C. Laparoscopic inguinal herniorrhaphy in children: a three centre experience with 933 repairs. J Pediatr Surg. 2002;37:395–397 . [Pub Med]
- [5]. Manoharan S, Samarakkody U, Kulkarni M, Blakelock R, Brown S. Evidence based change of practice in the management of unilateral inguinal hernia. J Pediatr Surg. 2005;40:1163–1166 . [Pub Med]