

MRI Evaluation of Intramedullary Tumors of Spine in Adult and Pediatric Population- A Study at Tertiary Care Centre

Santosh K. Panda¹, Biswanath Nayak¹, Madhuri Panigrahi², Palash Das^{3*}

¹. Asst. Professor, Dept. Of Radiodiagnosis, P.R.M. Medical College, Baripada, Odisha, 757001, India

². Senior Resident, Dept. Of Physiology, Aims Bhubaneswar, Odisha, 751019, India.

³. Asst. Professor, Dept Of Pediatrics, KIMS, Patia, Bhubaneswar, Odisha, 751024, India.

Corresponding author: Santosh K. Panda

Abstract:

Objective: Different tumor and tumor like conditions can affect spinal cord and its supporting structures. They can affect both adults and children. They can lead to severe neurological deficits and several morbidities if not diagnosed in time and treated accordingly. Aim of our study was to assess the distribution, features, localization and extent of tumors of spine at intra-dural region by MRI and to correlate it with the pathology diagnosis.

Methods: A total of 116 no of patients diagnosed with tumors of spine by MRI and underwent surgery were provisionally taken for study. Extradural tumors were excluded from study group so that our study included 89 no of patients having intradural tumors. The study was conducted in the departments of Radiodiagnosis, Neurosurgery, and Pathology at SCBMCH, Cuttack, and KIMS, Patia, Bhubaneswar, Odisha, India, from January 2014 to December 2016. It was a retrospective analytical type of study.

Results: Out of the 89 patients with intradural spinal tumors, 51 (57.3%) were male and 38 were female (42.7%). Among them 5.6% were in the pediatric age group and 94.4% were adults. In the pediatric age group, 20% of the cases were males and 80% were females. In the adults, 59.5% were males and 40.5% were females. Schwannoma was the commonest of the tumors accounting for 34.8%. Other tumors in decreasing order of frequency were meningiomas (20.2%), ependymomas (15.7%), neurofibromas (12.5%), astrocytomas (4.5%), metastases (3.4%), hemangioblastoma (2.6%), arachnoid cyst (3.4%), one each (1.1%) of lipoma and epidermoid cyst. Only Meningioma showed female predominance, Ependymoma showed no sex predilection and rest of the tumors were commoner in males than females. Majority of the tumors were seen in the intradural extramedullary compartment accounting for 69.7 % of the cases, followed by intramedullary tumors (20.2%) and rest were mix compartment tumors. Ependymoma was the commonest intramedullary tumor accounting for 38.9% of the intramedullary tumors with conus as the common site. Schwannoma was the commonest intradural extramedullary tumor accounting for 41.9% of them with thoracic as the common location. In adults, intradural extramedullary tumors are more common (67.4%) but in the pediatric age group, intradural-extramedullary and intradural-intramedullary tumors were of equal frequency. Out of 60 intradural extramedullary tumors in adults, schwannomas were the commonest followed by meningioma, neurofibroma, Ependymoma, arachnoid cyst and metastasis. In the pediatric age group, two cases were noted in the intradural extramedullary compartment and those were schwannoma and ependymoma. In the intramedullary compartment in adults, ependymomas were the commonest tumors followed by astrocytoma. In the pediatric age group two cases of intradural-intramedullary tumors were found, one was ependymoma, other one metastatic. Out of 89 cases, MRI diagnosed 79 cases correctly. Out of the 10 wrongly diagnosed cases, 6 were intradural-extramedullary and 4 were intradural-intramedullary in location. MRI correctly diagnosed 88.76% of the intradural spinal tumors. MRI could correctly diagnose 90% of the intradural extramedullary tumors and 77.78% of the intramedullary tumors.

Conclusion: Majority of intradural tumors of spine occur in adults and very less frequency in pediatric population. MRI can accurately assess the distribution, features, localization, extent and the type of tumor in case of the spinal cord tumors in both adult and pediatric age group.

Keywords: Magnetic resonance imaging (MRI), spinal tumors, intradural, extramedullary, intramedullary.

Date of Submission: 16-06-2018

Date Of Acceptance: 02-07-2018

I. Introduction

A spinal tumor is an abnormal mass of tissue within or surrounding the spinal cord and spinal column [1]. Earlier xray-myelography, postmyelography CT scan and bone scans and CSF fluid analysis were used for evaluation of possible tumors of spine and spinal cord. Nowadays, MRI is the most commonly used

radiological modality for spinal cord imaging [2,3]. Central nervous system comprises of brain and spinal cord. Spinal cord tumors account for 2-4% of all central nervous system neoplasms [4, 5]. Spinal cord tumors can be grouped according to their location into extradural, intradural extramedullary and intramedullary tumors which help in diagnosis of type of tumor. Lesions can occasionally compromise more than one compartment [1]. Intradural compartment comprises of intradural Extramedullary and Intramedullary lesions [3,6,7,8]. Intradural extramedullary tumors are seen within the dural sheath but outside the spinal cord [7,8]. Neurofibroma and meningioma are the common primary tumors in this location which are commoner than the secondary tumors or leptomeningeal tumor spread [3]. These lesions cause widening of the subarachnoid space [7]. Intramedullary tumors occur within the spinal cord resulting in cord expansion and narrowing of subarachnoid space [5,7]. Most of the intramedullary tumors are malignant and 90-95% are gliomas. Commonly the glial tumors are ependymoma and astrocytoma. In adults, ependymomas are the commonest glial tumors and in children astrocytomas are common intramedullary. Intramedullary metastasis is extremely rare [3, 9]. Spinal tumors present with symptoms like back pain, progressive paraparesis, sensory loss, sphincter dysfunction [9, 10].

Aim of study was to assess the distribution, features, localization and extent of spinal tumors by MRI and to correlate the tissue characterization by MRI with that of pathological examination as reference.

II. Method

It was a retrospective analytical study conducted in the Department of Radio-diagnosis, Neuro-Surgery and Pathology, S.C.B. Medical College and KIMS, Patia, Bhubaneswar, from January 2014 to December 2016. A total of 116 no of patients diagnosed of spinal tumors by MRI and underwent surgery were considered for study initially, out of which extradural lesions were excluded, so that only 89 of patients with intradural lesions were included in study. History was taken and the patients were clinically examined. Those patients diagnosed as having spinal cord tumors were followed up till surgery for confirmatory Histo-pathological/Cytological diagnosis. Patients of both adult and pediatric age groups belonging to either sex with intradural spinal tumors diagnosed by MRI spine were included in the study. Those patients with spinal symptoms/pathology due to extradural tumors, infections, prolapsed intervertebral disc, and trauma were excluded from the study. All the MRI scans in this study were performed using GE Signa HDX MR Machine with 1.5 tesla field strength. Precontrast images were taken followed by postcontrast images with intravenous administration of 0.1 mmol/kg of body weight of gadolinium. The MRI imaging protocol used are as below.

Table 1-MRI Protocol

Sequence	TR	TE	FOV (cm)	Slice thickness (mm)	Inter slice gap (mm)	Imaging Matrix	NEX
T2 SAGITAL	2760	110.0	32 x 32	4	1	512 x 256	3
T1 SAGITAL	760	15	32 x 32	4	1	256 x 256	2
T2 AXIAL	2720	85	20 x 20	4	0.5	512 x 256	2
T1 AXIAL	780	20	20 x 20	4	0.5	512 x 256	2
CORONAL STIR	3750	26	32 x 32	4	0.5	512 x 512	2
Postcontrast T1 SAG FAT SAT	760	15	32 x 32	4	1	256 x 256	4
Postcontrast T1 COR FAT SAT	700	15	32 x 32	4	1	512 x 512	4
Postcontrast T1 AX FAT SAT	640	20	20 x 20	4	0.5	512 x 256	3

The obtained data were analyzed by using a software statistical package for the social science (SPSS version 20). Frequency and descriptive analyses were used to describe the data. Any difference or correlation was considered significant if p value less than 0.05.

III. Results

Table 2: Age and gender distribution of intradural spinal tumors

Age(Years)	Male		Female		Total		Male	No	%
	No.	%	No	%	No	%			
0-18	1	2	4	10.5	5	5.6	Female	38	42.7
19-30	10	19.6	2	5.3	12	13.5	Total	89	100
31-40	9	17.6	9	23.7	18	20.2			
41-50	16	31.4	16	42.1	32	36			
51-60	7	13.7	6	15.8	13	14.6			
>60	8	15.7	1	2.6	9	10.1			
TOTAL	51	100	38	100	89	100			

Out of the 89 patients with intradural spinal lesions, 51 (57.3%) were male and 38 were female (42.7%). Among them 5.6% were in the pediatric age group and 94.4% were adults. In the pediatric age group, (1 out of 5) 20% of the cases were male and (4 out of 5) 80% were females. In the adults, 59.5% (50 out of 84) were males and 40.5% (34 out of 84) were females.

Table 3: Age group and gender distribution of individual intradural tumors

	Tumors	%	Sex		Age (Years)						
			M	F	0-10	11-20	21-30	31-40	41-50	51-60	>60
1	Schwannoma (31)	34.8	17	14	1	1	5	9	9	6	-
2	Meningioma (18)	20.2	6	12	-	-	-	3	9	3	3
3	Ependymoma (14)	15.7	7	7	1	1	2	2	5	1	2
4	Neurofibroma (11)	10.5	8	3	-	1	-	1	4	2	3
5	Astrocytoma (4)	4.5	4	0	-	-	1	1	-	1	1
6	Metastasis (3)	3.4	3	0	-	1	-	-	2	-	-
7	Hemangioblastoma (3)	3.4	2	1	-	-	1	1	1	-	-
8	Arachnoid Cyst (3)	3.4	2	1	-	1	-	-	2	-	-
9	Lipoma (1)	1.1	1	0	-	-	-	1	-	-	-
10	Epidermoid Cyst (1)	1.1	1	-	-	-	1	-	-	-	-

Schwannoma was the commonest of tumors accounting for 34.8% of the tumors. Other tumors in decreasing order of frequency were meningioma (18 in no., 20.2%), ependymoma (14 in no, 15.7%), neurofibroma (11 in no, 12.5%), astrocytoma (4 in no, 4.5%), metastases (3 in no, 3.4%), hemangioblastoma (3 in no, 3.4%), arachnoid cyst (3 in no, 3.4%), one each (1.1%) of lipoma and epidermoid cyst (table-3). Only Meningioma showed female predominance. Ependymoma showed no sex predilection. Rests of the tumors were commoner in males than females.

Table 4: Compartmental distribution of the intradural spinal tumors

Intramedullary	No	Intradural extramedullary	No	Both Intra-Extradural	No	Both Intra-Extra Medullary	No
Ependymoma	7	Schwannoma	26	Neurofibroma	3	Ependymoma	1
Astrocytoma	4	Meningioma	18	Schwannoma	5		
Hemangioblastoma	3	Neurofibroma	8				
Lipoma	1	Arachnoid Cyst	3				
Epidermoid Cyst	1	Ependymoma	6				
Metastatic	2	Metastatic	1				
TOTAL	18		62		8		1

Majority of the tumors were seen in the intradural extramedullary compartment accounting for 69.7 % of the cases, followed by intramedullary tumors (20.2%) and rest were mix compartment tumors. Ependymoma was the commonest intramedullary tumor accounting for 38.9% (7 out of 18) of the intramedullary tumors. Schwannoma was the commonest intradural extramedullary tumor accounting for 41.9% (26 no. out of 62) of them.

Table 5: Distribution of tumors in adult & pediatric age group

	Intradural intramedullary		Intradural extramedullary		Both Intra-Extradural		Both Intra-Extramedullary	
	No	%	No	%	No	%	No	%
Adults	16	18	60	67.4	7	7.8	1	1.1
Pediatric	2	2.2	2	2.2	1	1.1	-	-

In adults, intradural extramedullary tumors are more common (60 out of 89, 67.4%). In the pediatric age group, intradural Extramedullary and Intramedullary tumors accounted equal in frequency.

Table 6: Distribution of intradural extramedullary tumors in adults and pediatric group

Adult intradural extramedullary tumors (n=60)			Pediatric intradural extramedullary tumors (n=2)
Tumor	No	%	
Schwannoma	25	41.7	1
Meningioma	18	30	
Neurofibroma	8	13.3	
Ependymoma	5	8.3	1
Arachnoid Cyst	3	5	
Metastatic	1	1.7	

Out of 60 intradural extramedullary tumors in adults, schwannomas were the commonest followed by meningioma, neurofibroma, Ependymoma, arachnoid cyst and metastasis. In the pediatric age group, two cases were noted in the intradural extramedullary compartment and those were schwannoma and ependymoma.

Table 7: Distribution of intradural intramedullary tumors in adults and pediatric group

Adult intradural intramedullary tumors (n=16)			Pediatric intradural intramedullary tumors (n=2)
Tumors	No	%	
Ependymoma	6	37.5	1
Astrocytoma	4	25	
Hemangioblastoma	3	18.7	
Epidermoid Cyst	1	6.3	
Lipoma	1	6.3	
Metastatic	1	6.3	1

In the intradural-intramedullary compartment in adults, ependymomas were the commonest tumors followed by astrocytoma. In the pediatric age group two cases of intradural intramedullary tumors were found, one was ependymoma, other one metastatic.

Table 8: Location distribution of intradural extramedullary tumors

Tumors (n=62)	Cervical	Thoracic	Lumbo-sacral
Schwannoma (26)	5	14	7
Meningioma (18)	3	13	2
Neurofibroma (8)	2	4	2
Ependymoma (6)		3	3
Arachnoid Cyst (3)	-	2	-
Metastatic (1)			1

Schwannoma was commonest intradural extramedullary tumor followed by meningioma with thoracic as the common location.

Table 9: Location distribution of intradural intramedullary tumors

Tumors (n=18)	Location		
	Cervical	Thoracic	Conus medullaris
Ependymoma (7)	1	-	6
Astrocytoma (4)	1	2	1
Hemangioblastoma (3)	-	2	1
Metastatic (2)	-	1	1
Epidermoid Cyst (1)	-	1	-
Lipoma (1)	1	1	-

Ependymoma was commonest intradural-intramedullary tumor with conus as the common site.

Table 10: Pathological examination as compared with MRI diagnosis

	Lesions	Pathological Diagnosis	MRI Diagnosis
1.	Schwannoma	31	27
2.	Meningioma	18	18
3	Ependymoma	14	12
4	Neurofibroma	11	9
5.	Metastases	3	2
6	Astrocytoma	4	3

7	Hemangioblastoma	3	3
8	Arachnoid Cyst	3	3
9	Epidermoid Cyst	1	1
10	Lipoma	1	1
	Total	89	79

Out of 89 cases, MRI diagnosed 79 cases correctly. Out of the 10 wrongly diagnosed cases, 6 were intradural- extramedullary and 4 were intradural intramedullary in location. MRI correctly diagnosed 88.76% of the intradural spinal tumors. MRI could correctly diagnose 54 out of 60 (90%) of the intradural extramedullary tumors and 14 out of 18 (77.78%) of the intramedullary tumors (table-10).

Table 11: Following intradural tumors were wrongly diagnosed by MRI

Sl. No	Age (Years)/Sex	Pathological Diagnosis	MRI Diagnosis
1	40/M	Astrocytoma	Ependymoma
2	40/F	Schwannoma	Neurofibroma
3	55/F	Neurofibroma	Schwannoma
4	56/M	Neurofibroma	Meningioma
5	36/M	Schwannoma	Ependymoma
6	35/F	Schwannoma	Neurofibroma
7	35/F	Schwannoma	Ependymoma
8	5/F	Ependymoma	Astrocytoma
9	58/F	Ependymoma	Astrocytoma
10	8/M	Neurofibroma	Schwannoma

MRI wrongly diagnosed the above 10 cases. Two of the cases diagnosed on MRI as neurofibromas were found to be schwannomas on pathological examination and vice versa. Similarly two cases of astrocytoma came out ependymoma, two of ependymoma came out to be schwannoma and one as astrocytoma. Also one case of meningioma came out to be neurofibroma (table-11).

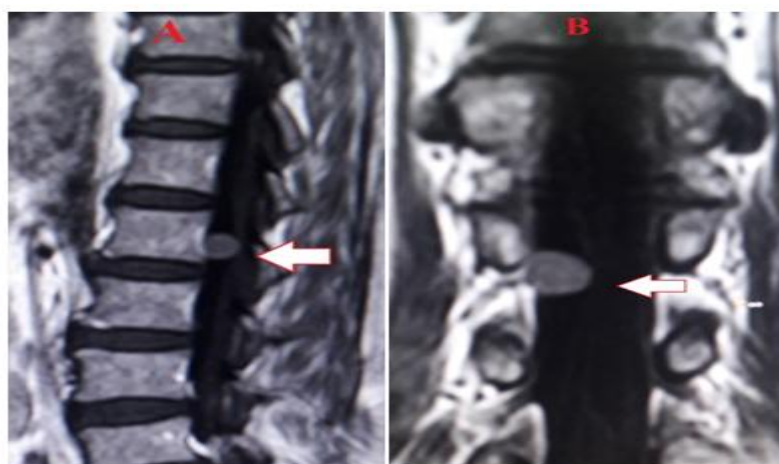


Fig- 1: Sagittal (A) and coronal (B) post contrast T1 images showing a dural based extramedullary tumor, diagnosed to be meningioma.

IV. Discussion

According to our study, intradural spinal lesions were common in adults and in male population (Table-2). Similar to ours, in the study conducted by Chung et al. [6] mentioned that out of the spinal tumor patients, 46.2% were males and 53.8% were females and 97.4% were adults.

Schwannoma was the commonest of tumors accounting for 34.8% of the tumors. Other tumors in decreasing order of frequency were meningioma (fig-1), ependymoma, neurofibroma, astrocytoma, metastases, hemangioblastoma, arachnoid cyst, lipoma and epidermoid cyst (table-3). Chung et al. [6] reported schwannomas as the commonest tumor, similar to our study, followed by meningiomas, neurofibromas, arachnoid cysts.

In our study, Meningioma showed female predominance. Ependymoma showed no sex predilection. Rest of the tumors was commoner in males than females. The male to female ratio of the different tumors in our study was as follows, schwannoma 1.2:1, meningiomas 1:2, neurofibroma 2.7:1, hemangioblastoma and arachnoid cyst 2:1, ependymoma 1:1. Astrocytoma, metastases, lipoma and epidermoid cyst were seen only in

male (table-3). In the study by Chung et al. [6], the male:female ratio in different tumors was schwannoma 1.1:1, meningioma 1:4, neurofibroma 1:1, arachnoid cyst 1:1.

Majority of the tumors were seen in the intradural extramedullary compartment accounting for 69.7 % of the cases, followed by intramedullary tumors (20.2%) and rest were mix compartment tumors. Ependymoma was the commonest intramedullary tumor. Schwannoma was the commonest intradural extramedullary tumor (table-4). In the study by Chung et al. [6], intradural extramedullary tumors were the commonest. Similarly study conducted by Dr Ravi N et al found that intradural extramedullary (48.5%) tumors were commoner than intramedullary (23%) compartment tumors [2].

In adults, intradural extramedullary tumors are more common (67.4%). In the pediatric age group, intradural Extramedullary and Intramedullary tumors were equal in frequency.

Among the intradural-extramedullary tumors in adults, Schwannomas were the commonest followed by meningioma , neurofibroma , Ependymoma, arachnoid cyst and metastasis (table 6, 7). Chung et al. [6] reported schwannomas as the commonest intradural extramedullary lesion followed by meningioma and neurofibroma.

In our study, in the intramedullary region in adults, ependymomas were the commonest tumors followed by astrocytomas , hemangioblastoma, epidermoid cyst , lipoma and metastasis (table-7). Parizel et al. [11] also reported that ependymomas and astrocytomas are the two commonest tumors in adults. Engelhard et al. [12] also reported that ependymomas were the commonest intramedullary tumors.

Out of 89 cases, MRI diagnosed 79 cases correctly. Out of the 10 wrongly diagnosed cases, 6 were intradural- extramedullary and 4 were intradural intramedullary in location. MRI correctly diagnosed 88.76% of the intradural spinal cord tumors. MRI could correctly diagnose 90% of the intradural extramedullary tumors and 77.78% of the intramedullary tumors.

The specificity of MRI in diagnosing schwannoma was 87.1%. MRI was able to diagnose all cases of meningioma accurately. The specificity of MRI in diagnosing neurofibroma was 81.8% and for ependymoma it was 85.7% (table 11).

V. Conclusion

Majority of intradural tumors of spine occur in adults and very less frequency in pediatric population MRI can accurately assess the distribution, features, localization, and extent of spinal cord tumors in both adult and pediatric patients as well. MRI accurately characterized the tumor tissue in 88.76% of the intradural spinal tumors, 90% of the intradural-extramedullary tumors and 77.78% of the intramedullary tumors. Funding: No funding sources Conflict of interest: None declared Ethical approval: Not required

References

- [1]. A. M. Quiles, E. Gomez Rosello, G. Laguillo, R. Garcia, J.-L. Caro, F. Perez, S. Pedraza; A Comprehensive Review of Intraspinal tumors: Diagnostic, classification and radio-pathologic correlation : GIRONA/ES,10.1594/ecr2013/C-2112
- [2]. Dr Ravi N et al: MRI Evaluation of Different Spectrum of Spinal Tumors: SSRG International Journal of Medical Science (SSRG-IJMS) – volume 1 Issue 2 December 2014:pp14-30
- [3]. Dr Ravi N et al: MRI Evaluation of Different Spectrum of Spinal Tumors: SSRG International Journal of Medical Science (SSRG-IJMS) – volume 1 Issue 2 December 2014:pp14-30
- [4]. Constantini S, Houten J, Miller D, et al. Intramedullary spinal cord tumors in children under the age of 3 years. *J Neurosurg* 1996; 85: 1036–1043.
- [5]. Koeller KK, Rosenblum RS, Morrison AL. From the archives of the AFIP: neoplasms of the spinal cord and filum terminale—radiologic-pathologic correlation. *RadioGraphics* 2000; 20:1721–1749.
- [6]. Chung JY, Lee JJ, Kim HJ, Seo HY. Characterization of Magnetic Resonance Images for Spinal Cord Tumors. *Asian Spine Journal* 2008, Vol. 2, No. 1, pp 15–21.
- [7]. Pawha P, Sze G. Neoplastic disease of the spine and spinal cord. In: Atlas S, ed. *Magnetic resonance imaging of the brain and spine*. 4th ed. Philadelphia, Pa: Lippincott Williams & Wilkins, 2009; 1508–1564.
- [8]. Kocher B, Smirniotopoulos JG, Smith AB. Intradural spinal lesions. *Applied Radiology*. Sept 2009; 26-27.
- [9]. Smith AB, Soderlund KA, Rushing EJ, Smirniotopoulos JG. Radiologic-Pathologic Correlation of Pediatric and Adolescent Spinal Neoplasms: Part 1, Intramedullary Spinal Neoplasms. *AJR* 2012;198:34–43.
- [10]. Kim SH, Bak KH, Kim DW, Kang TH. Primary intramedullary spinal sarcoma : a case report and review of the current literatures. *J Korean Neurosurg Soc*. Nov 2010;48(5):448-51.
- [11]. Parizel PM, Balériaux D, Rodesch G, et al. Gd-DTPA-enhanced MR imaging of spinal tumors. *AJR Am J Roentgenol* 1989; 152:1087–1096.
- [12]. Engelhard HH, Villano JL, Porter KR, Stewart AK, Barua M, Barker FG II, Newton HB. Clinical presentation, histology, and treatment in 430 patients with primary tumors of the spinal cord, spinal meninges, or cauda equina. *J Neurosurg Spine* 2010;13:67–77.

Santosh K. Panda "MRI Evaluation of Intramedullary Tumors of Spine in Adult and Pediatric Population- A Study at Tertiary Care Centre." *IOSR Journal of Dental and Medical Sciences (IOSR-JDMS)*, vol. 17, no. 6, 2018, pp 33-38.