

## **Rare Case Of Ocular Burn From Button Battery**

M.Chokayri, K.Sbai, Mr.Bentouhami, Y.Hidan, A.Mchachi, L.Benhmidoune,  
R.Rachid

*Service D'ophtalmologie Adulte , Faculté De Médecine Et De Pharmacie , Université Hassan Ii -Casablanca ,  
Hôpital 20 Août 1953 , Chu Ibn Rochd , Maroc*

---

Date of Submission: 08-07-2024

Date of Acceptance: 18-07-2024

---

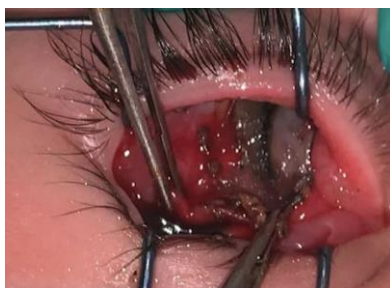### **I. Introduction:**

Button batteries are now widely used in a variety of household electronic devices, including children's toys, and cause severe tissue damage within two hours of exposure in the esophagus and nasal passages, which can lead to serious health problems and even perforation of vital tissue(1). Although cases of battery explosions causing eye damage have been documented, the extent of the damage caused by intact button cells is not fully understood (2, 3). Because of their small size, button batteries are easily swallowed by children or embedded in more unusual places such as nasal cavities or under the eyelids. Several studies have reported cases of ingestion of button batteries, mainly resulting in esophageal complications, but few cases have documented ocular exposure. We report a case of conjunctival necrosis following sub palpebral incarceration of a button battery.

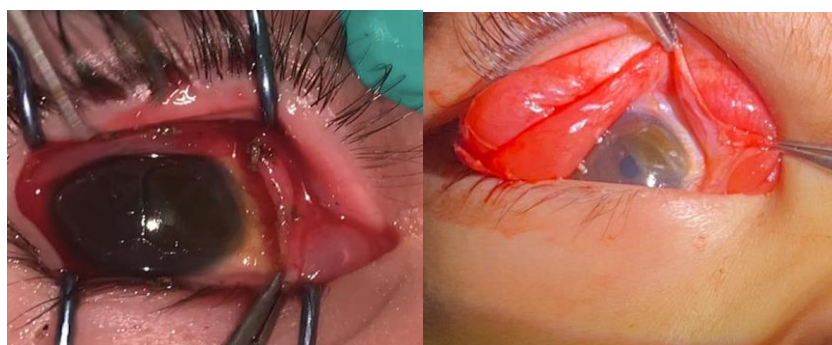
### **II. Case Report:**

The case involved a three-year-old boy who presented to the emergency with inflammatory oedema of the right eyelid with pain and reduced visual acuity, three hours after playing with an electric car containing a button cell battery. His upper eyelid was swollen, with pigmented and necrotic bulbar and tarsal conjunctiva (Figure 1). Fluorescein staining revealed corneal abrasion and limbal ischaemia extending from the 1 o'clock position to the 3 o'clock position (Figure 2). Further examination revealed a shiny metallic foreign body which was removed under topical anesthesia and the eye irrigated with 0.9% saline. A necrosectomy was performed and a symblepharon ring was placed.

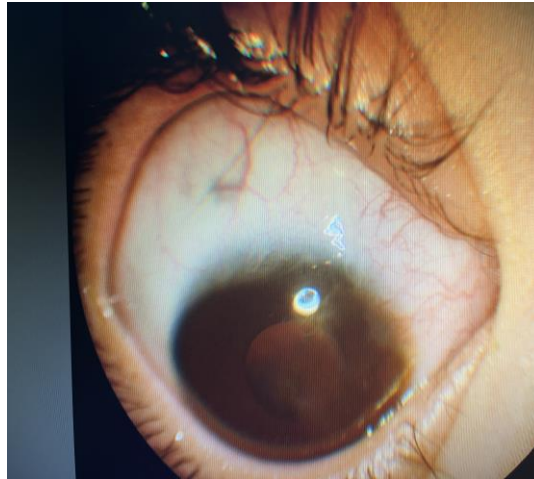
The patient was treated with topical antibiotics and steroids for one month, and the symblepharon ring was removed after three months (Figure 3), with a final best visual acuity of 7/10.



**Fig 1 : Conjunctival Pigmentation And Necrosis After Removing The Battery Button**



**Fig 2: Conjunctival And Corneal Abrasion And Pigmentation**



**Fig 3: 3 Months After Ocular Burn**

### III. Discussion:

Button batteries release an alkaline electrolyte solution when exposed to liquids, causing caustic burns to surrounding tissue and necrosis (4).

An electric current is generated after contact between the button cell and the local tissue, resulting in hydrolysis of the surrounding liquid and the generation of hydroxide ions which accumulate around the cathode, where alkaline damage is most severe. (1)

A Japanese case report described damage to the cornea and conjunctiva within 5 minutes of contact with a button cell on experimental pig eyes. The cornea and conjunctiva are damaged by continuous exposure to alkaline solution after the button cell penetrates the lacrimal sac, causing fixation by chemosis. Interestingly, in our case, the child developed severe symptoms 3 hours after insertion of the battery. Another case report described a 90-minute delay in presentation after eye injury from a fast-moving button cell battery, also with subsequent alkaline injury. (1) Deep positioning of the battery in the fornix, away from the sensitive corneal nerves, may have accounted for the delayed presentation.

Several factors contribute to the severity of the eye injury: the moist surface of the mucous membrane of the bulbar and tarsal conjunctiva, the close attachment of the battery between these two surfaces and immersion in the electrolyte-rich tear film, which contributes to the establishment of external electrical currents.

Increased public and professional awareness of the potential dangers of button batteries for young children is becoming a necessity. In the event of involvement, a detailed ocular examination with palpebral eversion, complete scanning of the fornixes and urgent removal of the button battery are necessary, an extraction that can be laborious in the case of young children and due to oedema in the event of delay. Delayed removal exposes tissues to permanent damage in the space of just a few hours, due to the high chemical toxicity.

Treatment should include immediate rinsing of the eye with a saline solution to dilute the caustic substances and normalise the pH of the ocular surface to between 7.0 and 7.2.

### IV. Conclusion:

The development of smaller batteries increases the risk of similar accidents. Burns caused by button cells can be serious and require accurate diagnosis and treatment, particularly in young children under the age of 6, who are difficult to assess (5).

Careers should take proactive steps to store button batteries safely and keep them out of children's reach. When using devices powered by button batteries, they should ensure that the battery compartments are properly secured and inaccessible to curious little fingers.

### References

- [1] G.Ratnarajan, D.Calladine, KJ Brid, S.L.Watson. Delayed Presentation Of Severe Ocular Injury From A Button Battery Bmj Case Rep. 2013 ; 2013: Bcr2013009094.
- [2] 12. Moore At, Cheng H, Boase DI. Eye Injuries From Car Battery Explosions. Br J Ophthalmol 1982;2013:141–4 [Pmc Free Article] [Pubmed] [Google Scholar]
- [3] 13. Minatoya Hk. Eye Injuries From Exploding Car Batteries. Arch Ophthalmol 1978;2013:477–81 [Pubmed] [Google Scholar]
- [4] Kavanagh Kt, Litovitz T. Miniature Battery Foreign Bodies In Auditory And Nasal Cavities. Jama 1986;255:1470-72.
- [5] M. Ogasawara , S.Goto, T. Shiba, K.Ohno, T.Shibata, K. Kouzaki, H.Tsuneoka A Case Of Button Battery-Induced Corneal And Conjunctive Burn Injury And Experimental Findings Of Local Damage. Nippon Ganka Gakkai Zasshi. 2011 Aug;115(8):711-7.